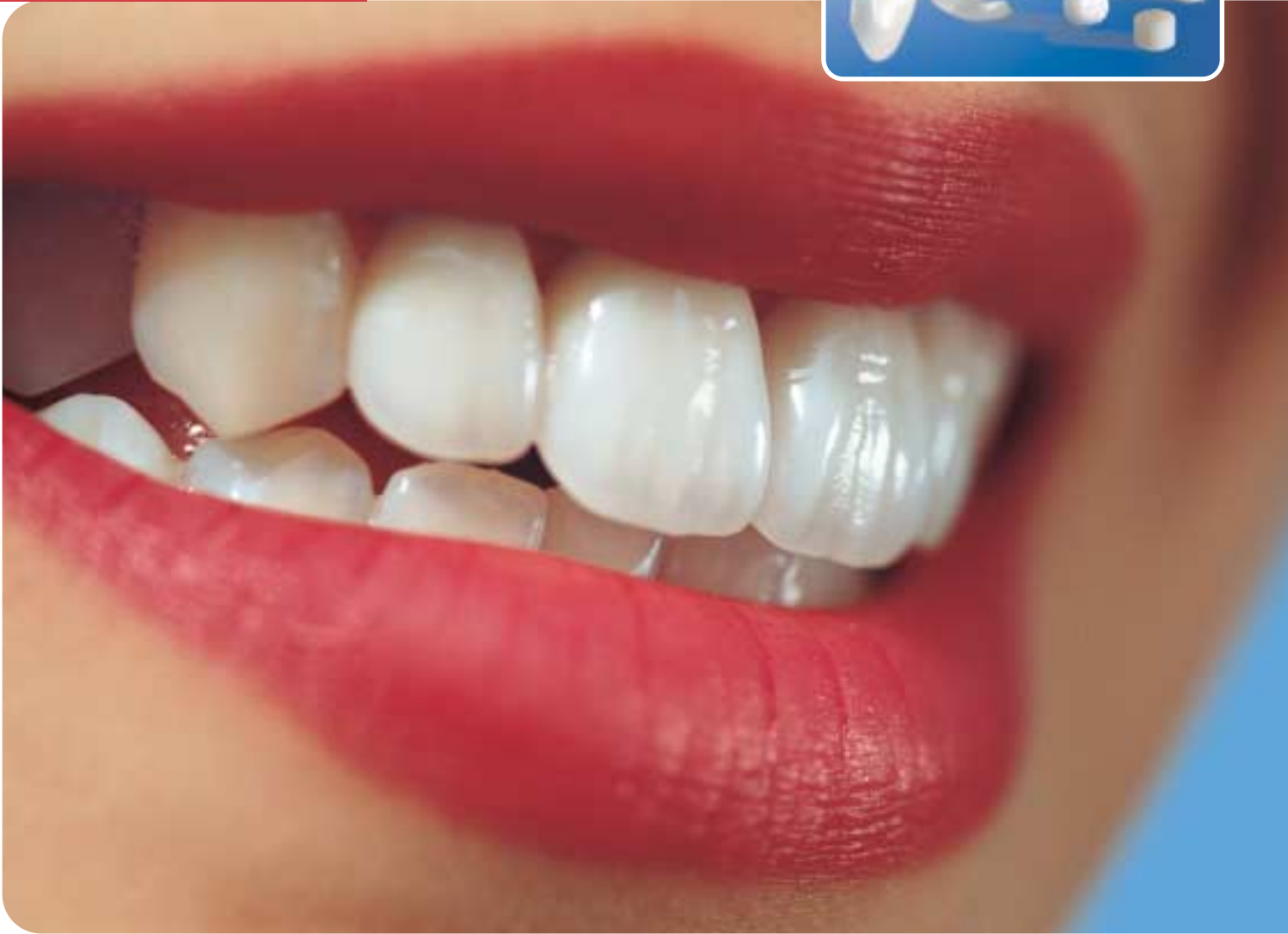

# IPS Empress® Esthetic

CLINICAL GUIDE





Introduction	4
Indications	5
Shade selection	6
Adhesive preparation (inlays, partial crowns, full crowns and veneers)	8
Impression taking	10
Temporary restoration	10
Cementation	11
Step by Step IPS Empress Esthetic veneer adhesively luted with Variolink II/Excite DSC	12
Step by Step IPS Empress Esthetic partial crown adhesively luted with Variolink II/Syntac	17
Finishing and polishing	22
Step by Step Adhesively luted IPS Empress Esthetic inlay, polished	22
Clinical long-term studies	25

## A tried-and-tested system

Aesthetics and longevity are important considerations for all-ceramics. The IPS Empress press-ceramic system has proven itself for more than 15 years as regards both criteria. Twenty-five million placed restorations are testimony to the durable true-to-nature effect, long-lasting success and the high quality standard of IPS Empress. Clinical studies, for example, show survival rates of 95% after 11 years.

With the new IPS Empress Esthetic Line for inlays, partial crowns, full crowns and veneers, the product family has been further enhanced. The result is an extremely homogeneous leucite glass-ceramic, which features natural light scattering and offers a balanced chameleon effect. Due to an increased density and homogeneity of the crystals, the restorations blend beautifully into the natural surroundings. Moreover, the flexural strength of the ingots has been improved from  $138 \pm 12$  MPa to  $160 \pm 8$  MPa. Objects fabricated using the lost-wax technique feature a particularly high accuracy of fit, as there is no sinter shrinkage.

IPS Empress Esthetic consists of



**IPS Empress Esthetic Ingots,**



the coordinated **IPS Empress Esthetic Speed** investment material



and the **IPS Empress Esthetic Veneer** layering materials.

The ingots are available in the popular Staining Technique shades as well as two new bright shades: E TCO and E OC1. With the layering materials, veneers and anterior crowns exhibiting outstanding aesthetic properties and accuracy of fit can be cost-effectively fabricated by applying a combined press/layering technique.

## For all single tooth indications

Indications	Luting material
Inlays 	Variolink II or Multilink
Partial coverage crowns 	Variolink II or Multilink
Anterior crowns 	Variolink II or Multilink
Posterior crowns 	Variolink II or Multilink
Veneers 	Variolink II

- ✓ 15 years of clinical experience with IPS Empress
- ✓ 25 million placed restorations
- ✓ Survival rate after 11 years: 95 %
- ✓ Clinically confirmed at numerous universities throughout the world
- ✓ Continuous further development of the IPS Empress Original System

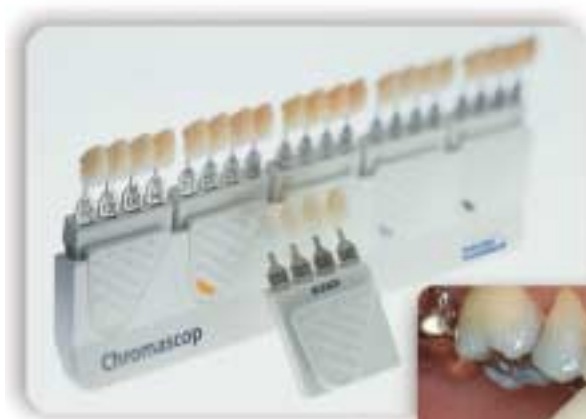## Aesthetic and true-to-nature

### Tooth shade selection

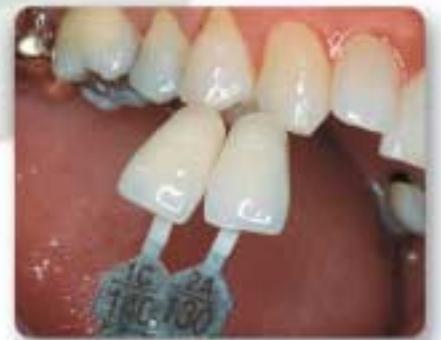The accurate shade is the basis for a true-to-nature restoration.

The tooth shade is determined on the cleaned, unprepared tooth or adjacent tooth with the help of the Ivoclar Vivadent Chromascop shade guide. Do not overdry the tooth before selecting the shade.

Observe individual characteristics when selecting the shade. If a crown preparation is planned, the incisal and cervical shades should also be determined. In order to achieve an optimum shade match, the shade should be taken under natural lighting conditions. In addition, patients should not wear brightly coloured clothes or lipstick during shade selection.



Shade guide for the tooth shade of the unprepared tooth

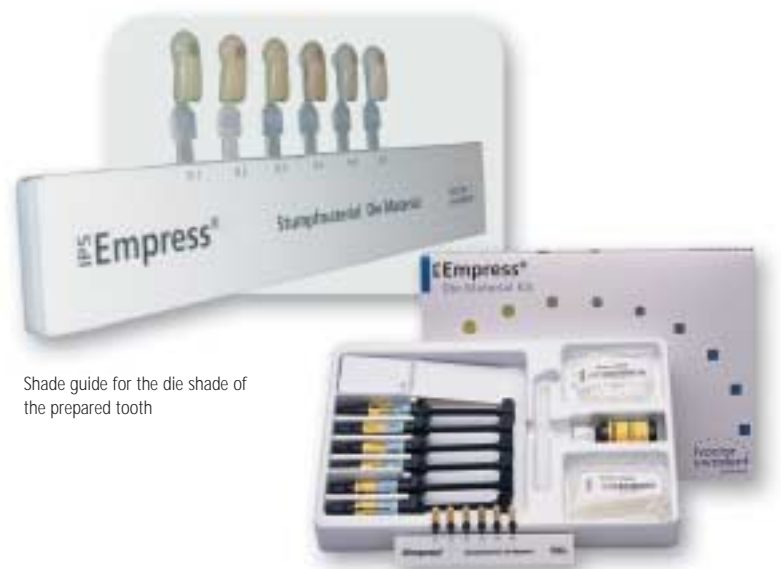

Shade determination on the patient

### Die shade selection

The shade of the prepared tooth may be determined using the IPS Empress die material shade guide. The shade of the prepared tooth and the desired tooth shade are critical for the selection of the ingot shade. The correct brightness value of the final shade is determined by the ingot material. Masking of a dark preparation is usually achieved by using an ingot that exhibits both a high degree of opacity and a lower colour intensity. The proper final shade is a combination of the following:

- ✓ die shade
- ✓ ingot
- ✓ staining or layering procedure
- ✓ cementation material



Shade guide for the die shade of the prepared tooth

IPS Empress Die Material Kit

## Defect-oriented and minimally invasive

### Preparation

Careful preparation is recommended for the durability and accuracy of fit of the restoration. IPS Empress Esthetic is adhesively cemented only. These instructions provide an overview of the preparation requirements for indirect restorations seated according to the adhesive technique. For further information, we recommend consulting the corresponding literature.

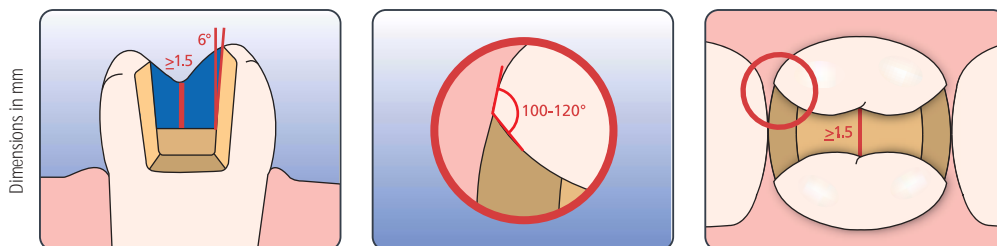
#### Basic rules:

- Complete a circular shoulder preparation with rounded internal line angles or a chamfer; the width of the shoulder/ chamfer should be at least 1 mm
- Do not prepare feather edges
- Avoid sharp edges and angles to prevent stress and to facilitate insertion
- The adhesive cementation procedure allows a defect-oriented preparation
- Strictly observe the necessary minimum wall thickness to ensure suitable stability of the restoration

### Inlays

Take antagonist contacts into consideration.

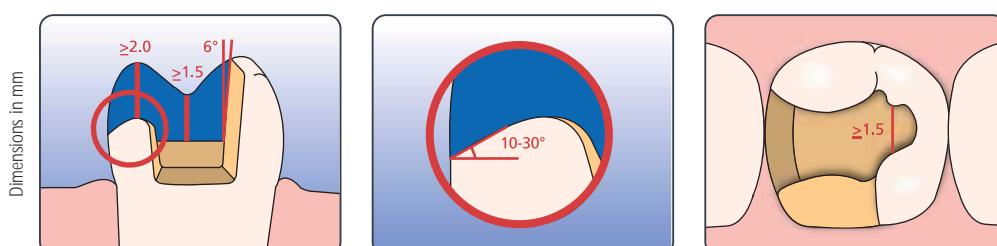
Observe a preparation depth of at least 1.5 mm in the central fissure area. The isthmus should be at least 1.5 mm wide. Complete the proximal box with a slightly diverging angle. Round out internal angles to avoid stress concentration in the ceramic. Eliminate proximal contacts. Do not prepare slice-cuts or feather edges.



### Partial crowns

Follow the same procedure described for inlays.

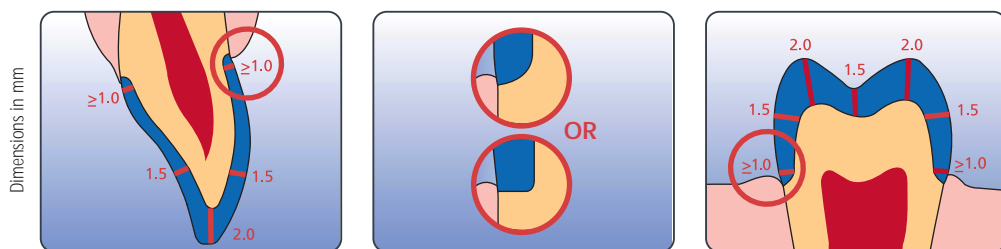
Observe a preparation depth of at least 1.5 mm in the central fissure area and an isthmus width of at least 1.5 mm. Provide 2 mm space in the area of the cusps and occlusal contacts. Prepare the shoulder with an incline (10°-30°) to improve the aesthetic appearance of the transitional area between ceramic material and tooth. Partial crowns are indicated if the preparation margin is located less than approx. 0.5 mm away from the cusp tip, or if the enamel is severely undermined.





### Full crowns Anterior and posterior crowns

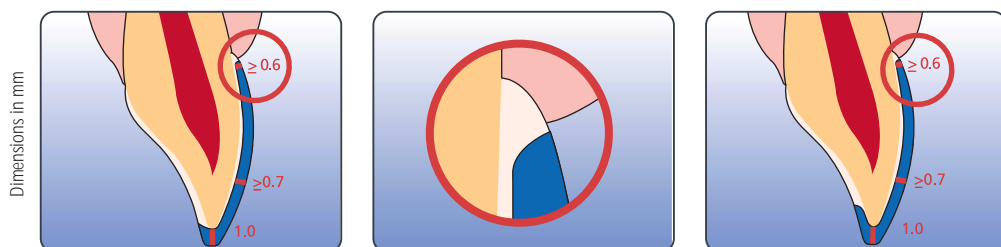
Evenly reduce the anatomical form, observing the stipulated minimum wall thickness. Prepare a circular shoulder with rounded internal angles or a chamfer. The width of the circular shoulder/chamfer should be approx. 1 mm. Reduce the axial walls of the tooth on the incisal third of the crown by approx. 1.5 mm. The incisal and/or occlusal reduction should be approx. 2 mm.



### Veneers

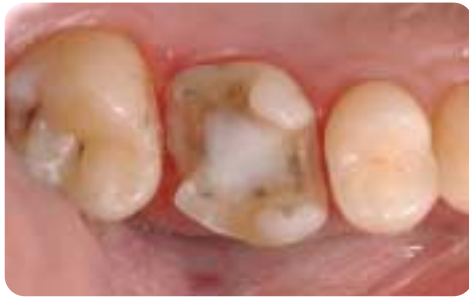If possible, the preparation should be entirely located within the enamel. Two techniques are available: the first involving a simple incisal reduction without reduction of the incisal edge and the other a classic preparation with lingual-incisal, chamfer-like preparation of the incisal edge. Margins should not be located in the occlusal contact areas.

The dimension of the incisal reduction depends on the desired degree of translucency of the incisal area to be restored. The more transparent the incisal edge of the veneer should appear, the more reduction is required. An incisal reduction of at least 1 mm is recommended. By providing depth grooves using the appropriate burs, controlled enamel reduction can be achieved. The minimum preparation thickness is approx. 0.6 – 1 mm depending on the preparation technique chosen. Eliminating proximal contacts is not necessarily required. Discoloured teeth may require more extensive reduction to allow for adequate masking. A cervical chamfer should be prepared.

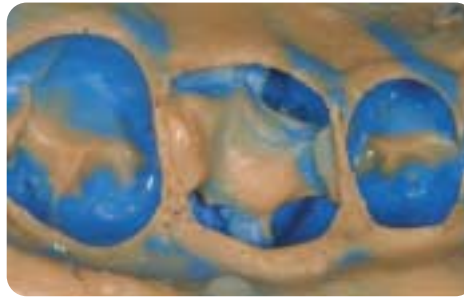


## Individual and precise

A polyvinyl siloxane silicone (e.g. Virtual®) or other suitable impression material may be used for the impression in the preferred impression taking technique.



Preparation for an IPS Empress Esthetic partial crown



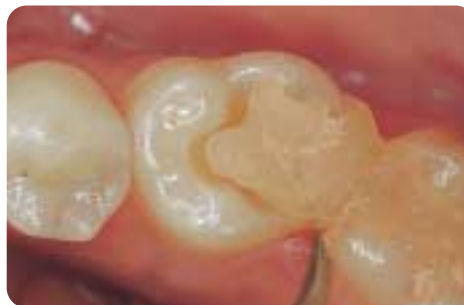Impression of the completed preparation

## Temporary restoration

Inlay and partial crown preparations may be restored with temporary restorative material (e.g. Systemp®.inlay/Systemp®.onlay).

Composite resin temporaries are the best solution for full crowns and veneers.

Use a temporary, eugenol-free cement for provisional cementation. Do not use cements that contain eugenol, as they may inhibit the polymerization of the luting composite used to place the permanent restoration.



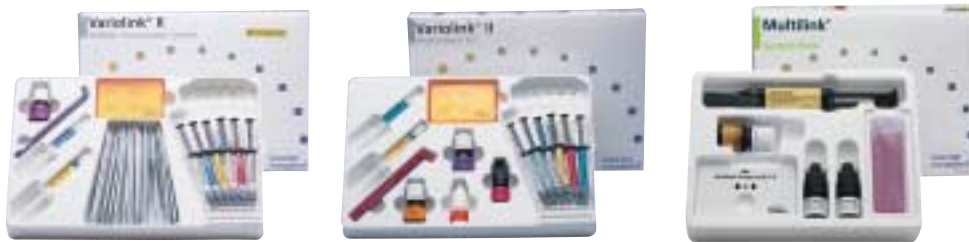Easy removal of the temporaries (Systemp.inlay/Systemp.onlay)



## Proven and coordinated

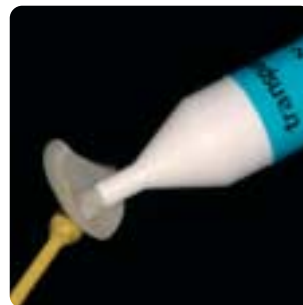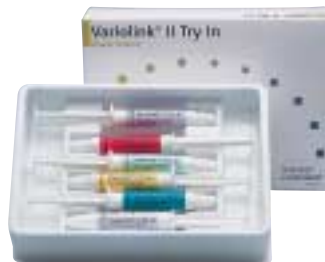### Variolink® II / Multilink®

IPS Empress Esthetic restorations have to be adhesively cemented. We recommend Variolink II (in combination with the dentin adhesives Syntac® or Excite® DSC) or Multilink for the cementation of inlays, partial crowns and full crowns. For IPS Empress Esthetic Veneers, only Variolink II is recommended.

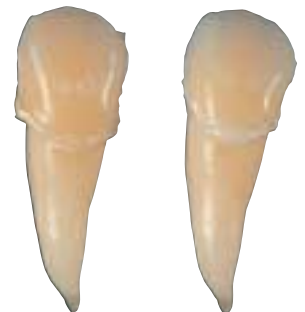

### Variolink II Try-In

The water-soluble Variolink II Try-In pastes allow the shade of the ceramic restoration to be simulated prior to final cementation. The Variolink II Try-In pastes feature the same optical properties as the subsequently used luting composite Variolink II.



Application of Variolink II Try-In on the inner aspects of the IPS Empress Esthetic Veneer.



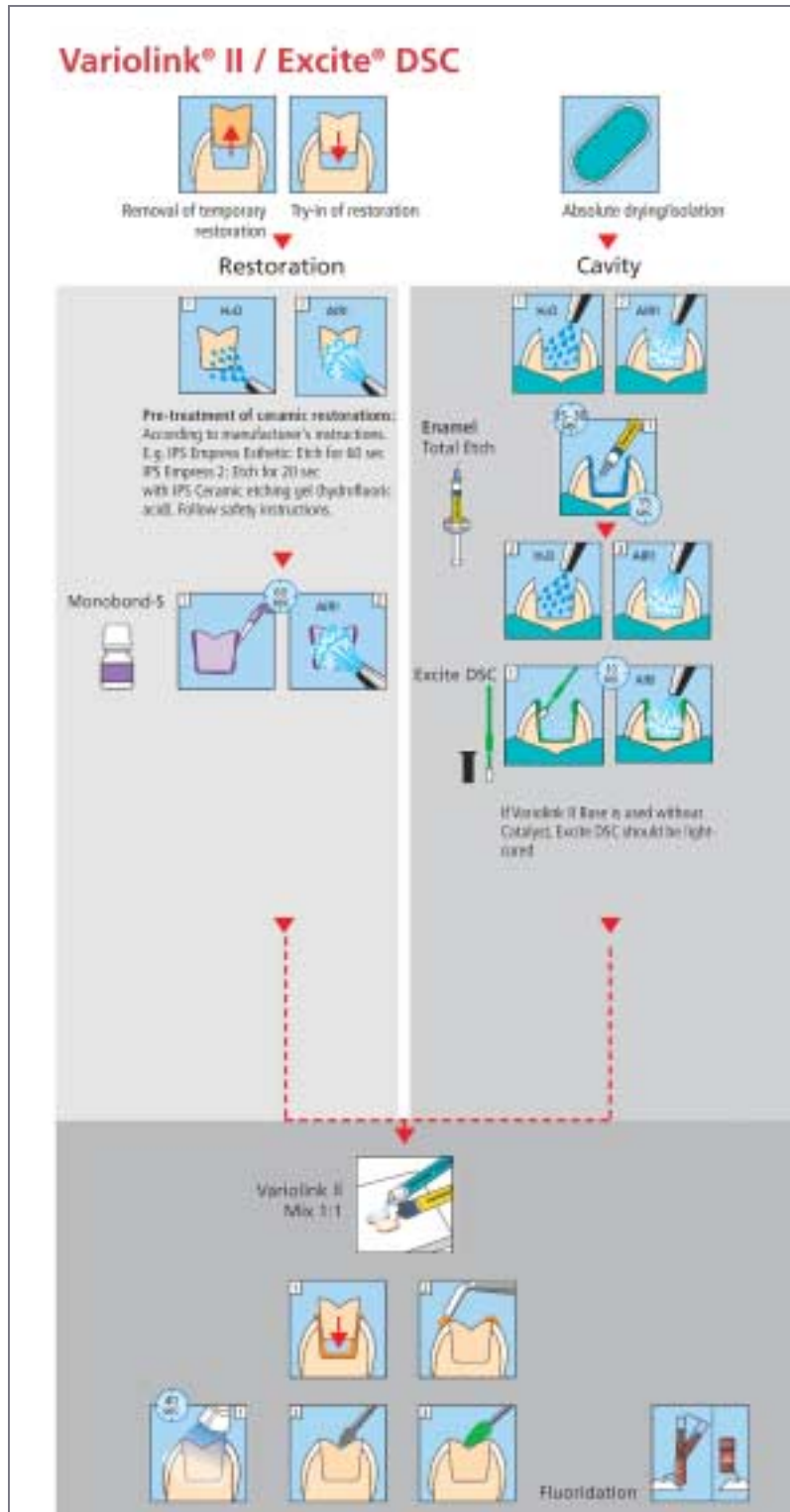
IPS Empress Esthetic Veneer tried in with Variolink II Try-In (shade yellow).

IPS Empress Esthetic Veneer tried in with Variolink II Try-In (shade transparent).

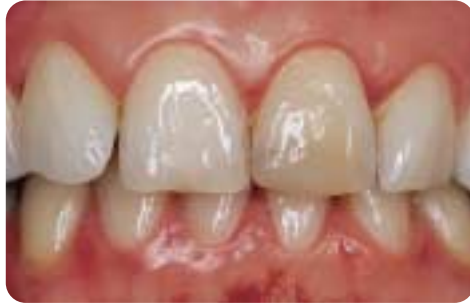# Clinical case: IPS Empress Esthetic Veneer adhesively luted with Variolink II/Excite DSC

Depending on the dentin adhesive in use, different procedures may be indicated.

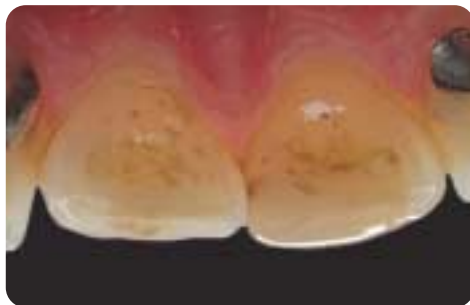Excite DSC is a dual-curing single-component adhesive with an innovative delivery.



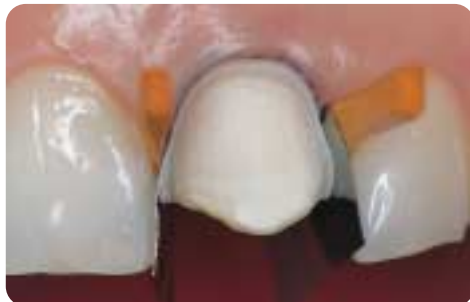Clinical case by Dr. Dr. Andreas Rathke / Urs Spirig



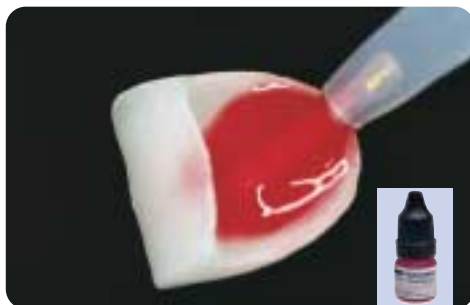Preoperative view:  
Patient with a large, discoloured incisal edge build-up made of composite in tooth 21.



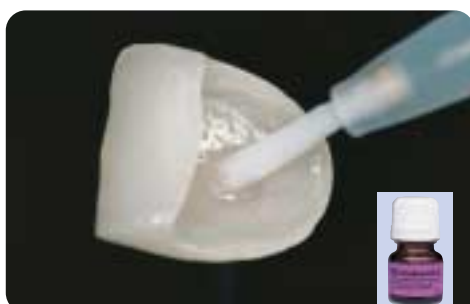The old composite build-up also comprises the palatal part of the incisal edge.



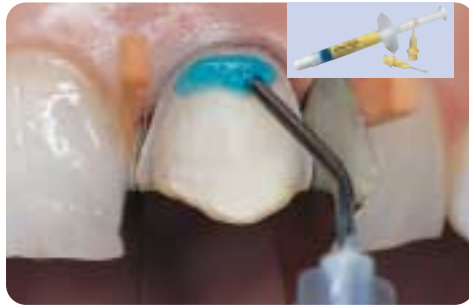Veneer preparation with palatal embrasure of the incisal edge after removal of the restoration. The tooth is prepared for adhesive cementation.



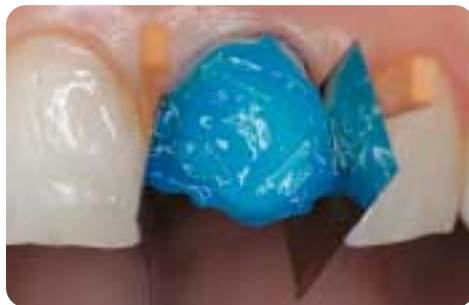Preparation of the IPS Empress Esthetic veneer: Etch the inner surfaces with IPS Ceramic Etching Gel (hydrofluoric acid) for 60 seconds, thoroughly rinse with water and dry with a stream of air.



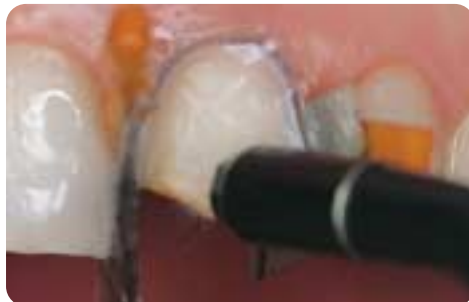Apply Monobond-S for 60 seconds on the inner aspects and dry.



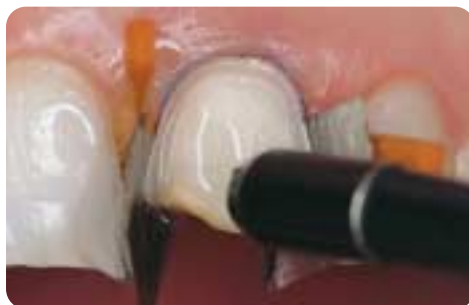Etch the enamel for at least 30 seconds with the Total Etch phosphoric acid etching gel.



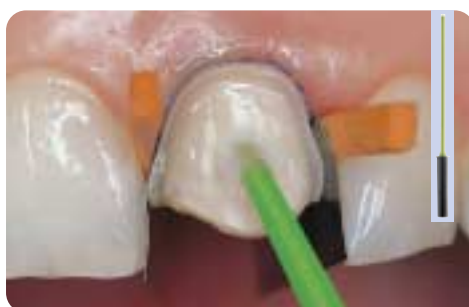Etch the dentin for 10-15 seconds with the Total Etch phosphoric acid etching gel.



Subsequently, rinse the phosphoric acid with water spray.

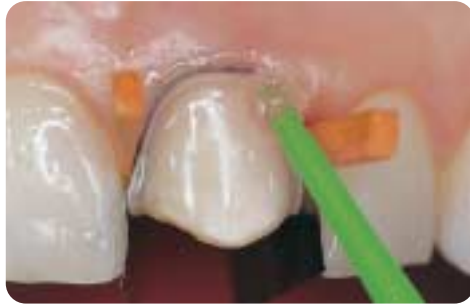

Next, apply dry moisture-free air across the surface to remove excess moisture. The dentin should remain slightly moist.

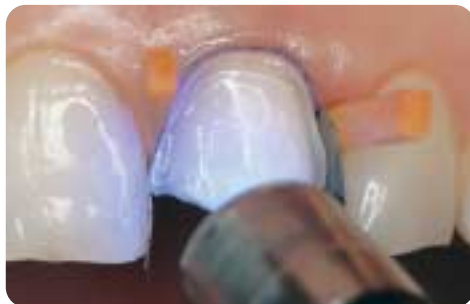

Apply Excite DSC adhesive on the slightly moist dentin.

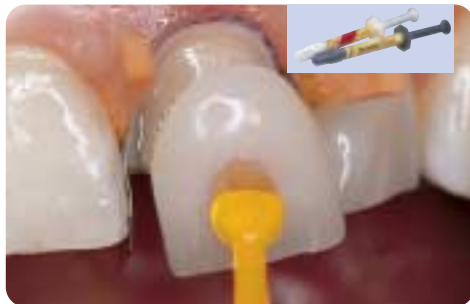



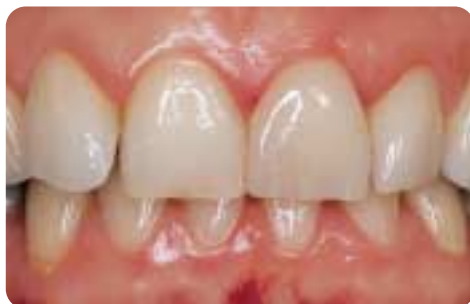Apply Excite DSC adhesive also on the enamel and disperse with air.



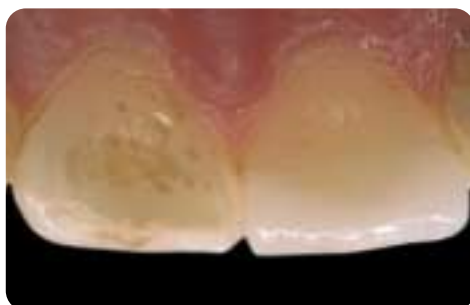
If a light-curing only resin cement is used (e.g. Variolink II Base without catalyst), light cure Excite DSC prior to placement (e.g. with bluephase®, LOP program, 10 seconds).



Place the veneer with Variolink II and light cure (e.g. with bluephase, HIP program).

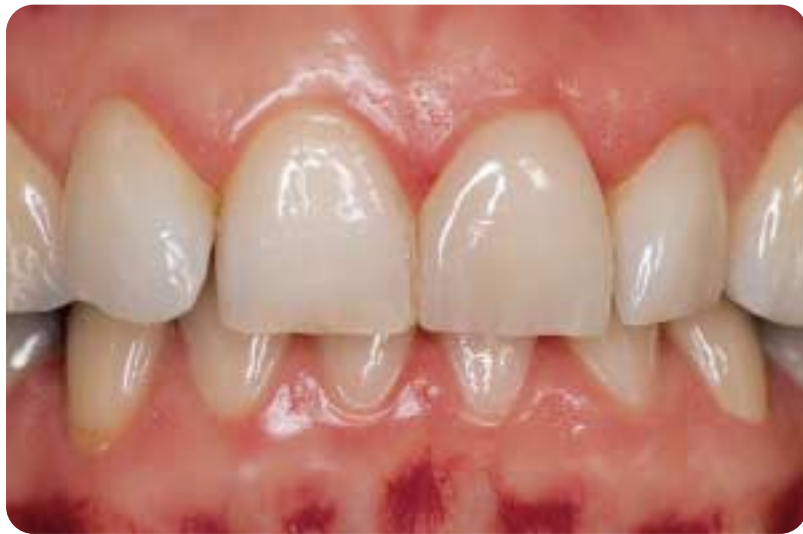
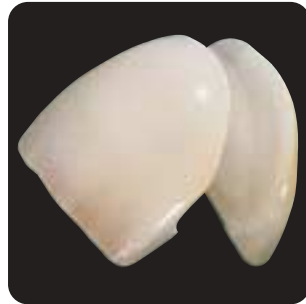
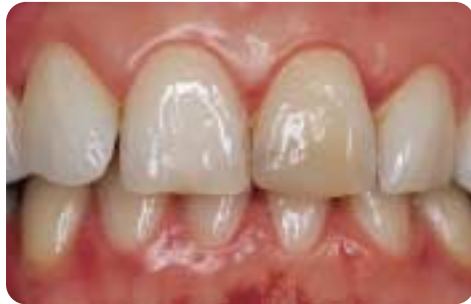Palatal view of the veneer on tooth 21.



The inserted veneer on tooth 21. Note the translucency of the incisal edge.

Before and after restoration with IPS Empress Esthetic

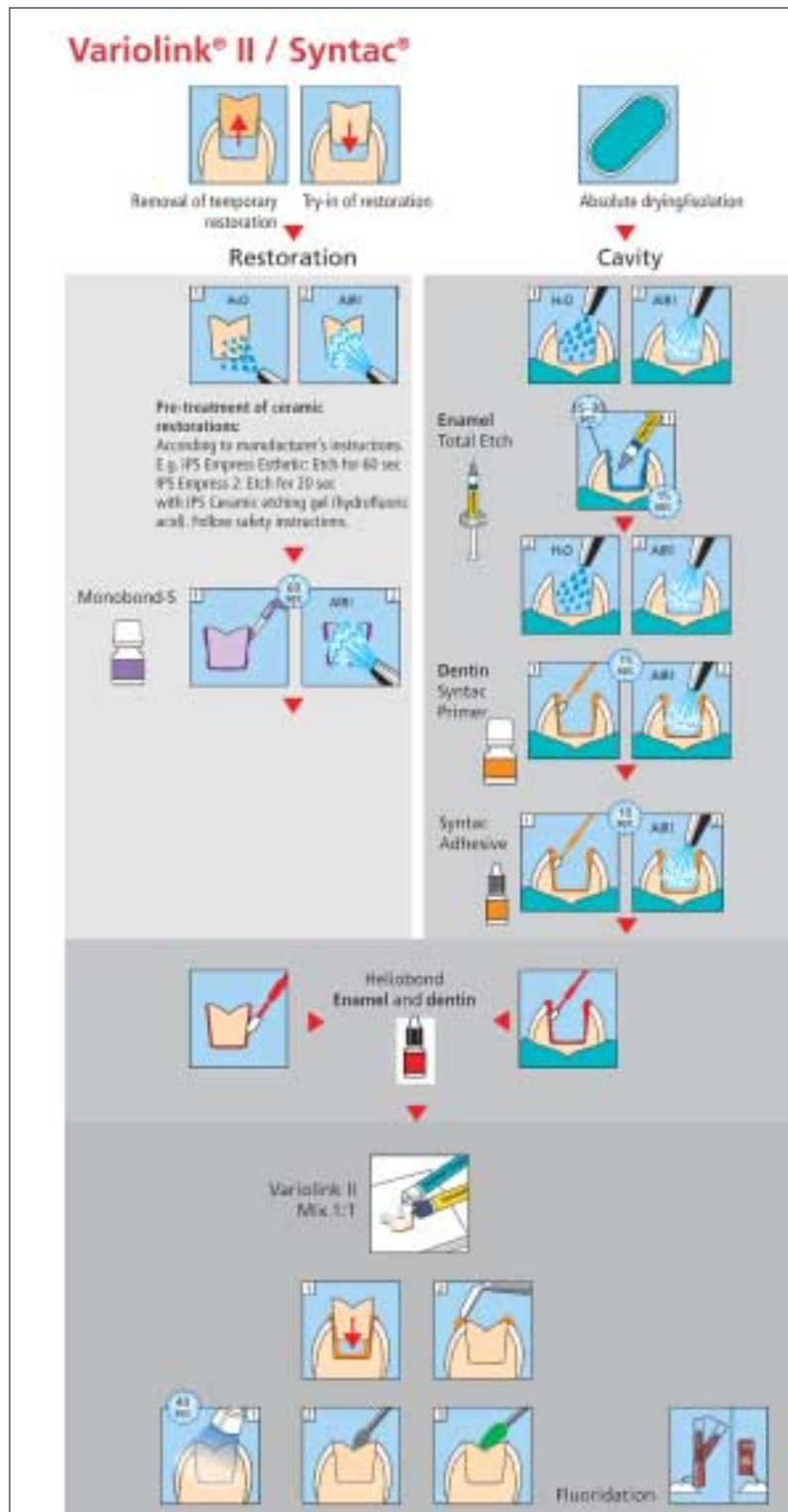




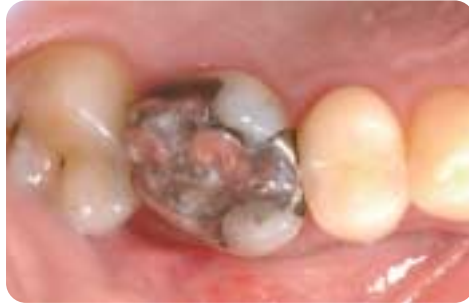## Clinical case: IPS Empress Esthetic partial crown adhesively luted with Variolink II/Syntac

Depending on the dentin adhesive in use, different procedures may be indicated.

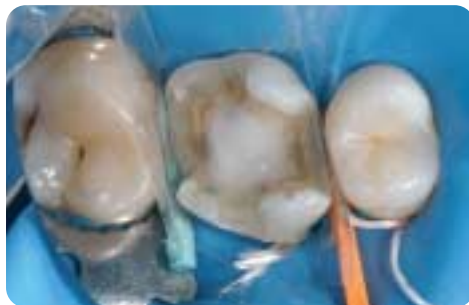Syntac is the proven multi-component adhesive. The bond to enamel and dentin is achieved by the successive applications of Syntac Primer, Syntac Adhesive and Heliobond. Syntac has been successfully used with more than 11 years of clinical success.



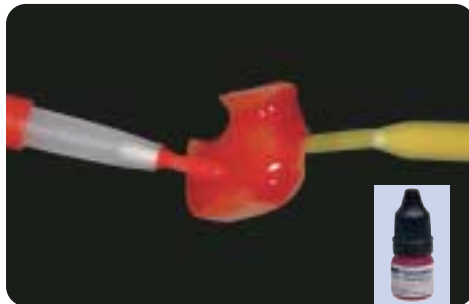Clinical case by Dr. Arnd Peschke / Katja Maier



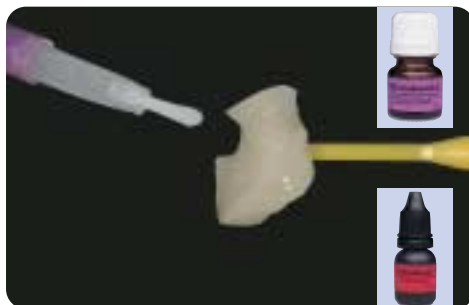
Preoperative view:  
Tooth 16 with defective amalgam filling and secondary caries.



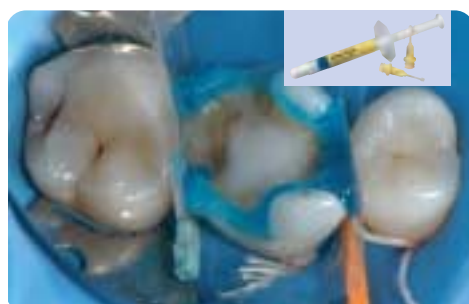Preparation for the partial crown after the restoration and caries have been removed. A rubber dam was placed for the adhesive cementation.



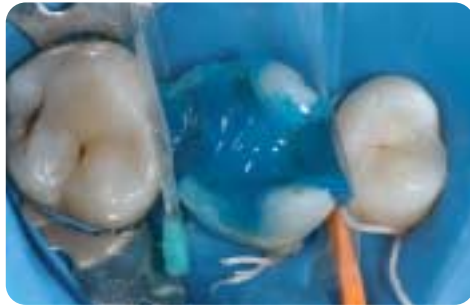Preparation of the IPS Empress Esthetic partial crown: Etch the inner aspects with IPS Ceramic Etching gel (hydrofluoric acid) for 60 seconds, thoroughly rinse with water and dry with a stream of air.



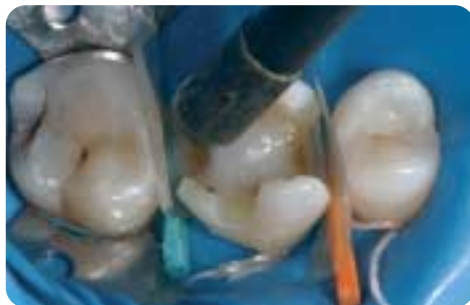Apply Monobond-S on the inner surfaces for 60 seconds and dry. Next, apply a thin layer of Heliobond and protect from light exposure until the insertion.



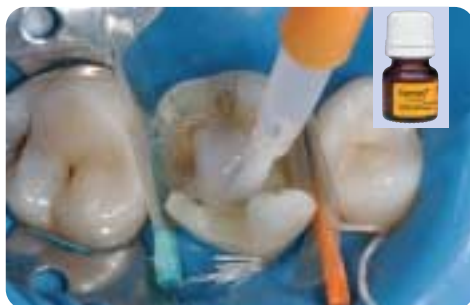Etch the enamel for at least 30 seconds with Total Etch phosphoric acid etching gel.



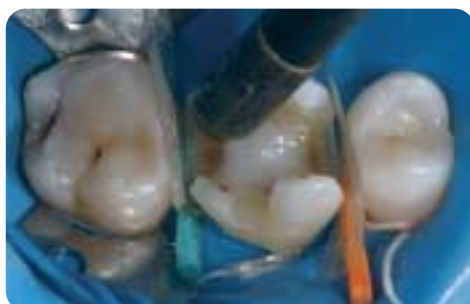If desired, etch the dentin for at least 10 seconds with Total Etch phosphoric acid etching gel.



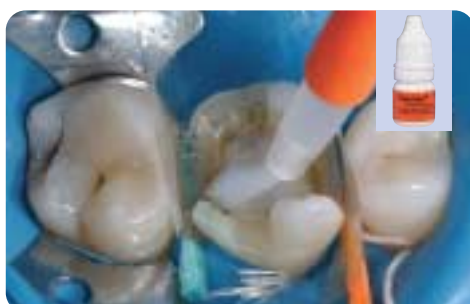Thoroughly rinse the phosphoric acid with water spray and dry with an air syringe.



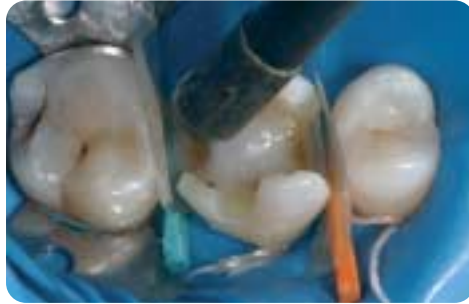Apply Syntac Primer on the dentin for at least 15 seconds.



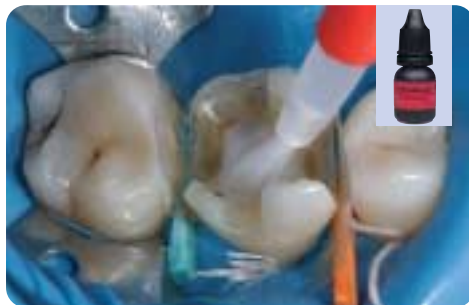Subsequently, dry the preparation with an air syringe.



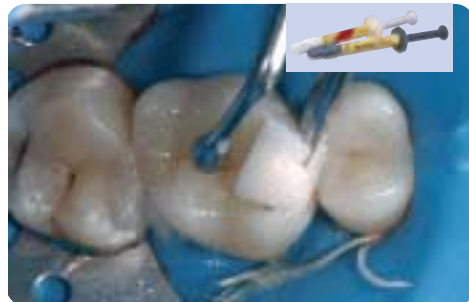Apply Syntac adhesive on the dentin for at least 10 seconds.



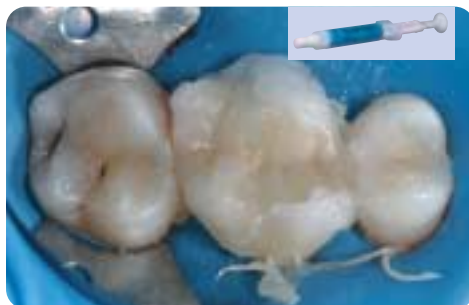
Next, dry the preparation with an air syringe.



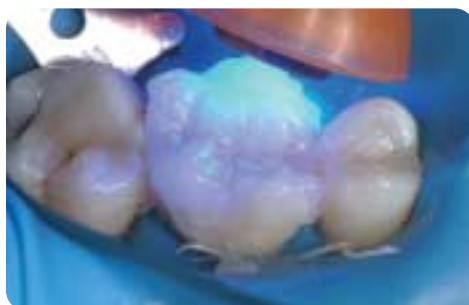Apply Heliobond on enamel and dentin.



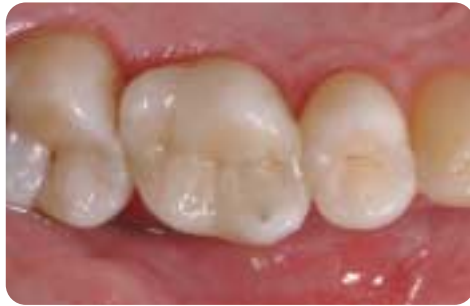Place the partial crown with Variolink II and remove excess material with foam pellets, brush or rubber tip instrument.



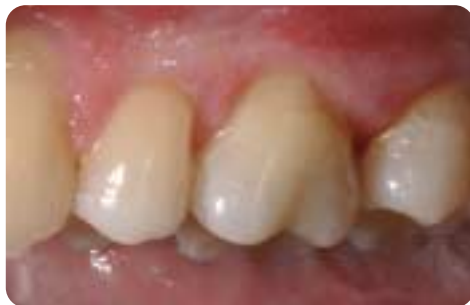Cover the margins with glycerine gel.



Light cure the inserted partial crown from all aspects (e.g. with bluephase, HIP program).

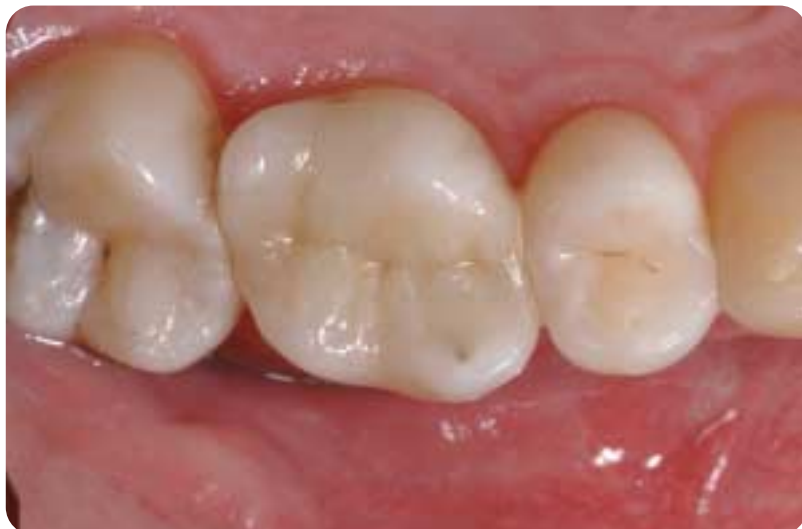
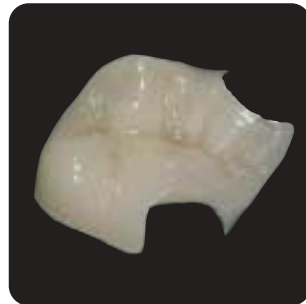
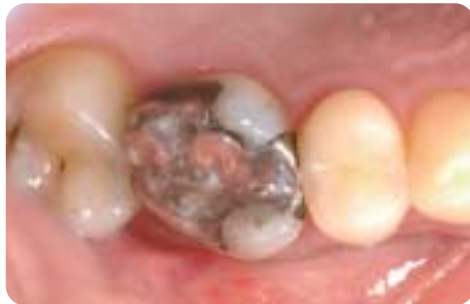The inserted partial crown on tooth 16.



Buccal view of the partial crown on tooth 16. The crown perfectly blends into the natural surroundings.

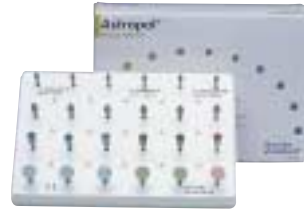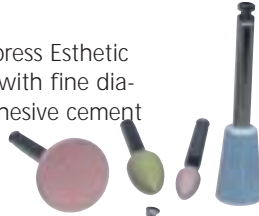## Before and after restoration with IPS Empress Esthetic



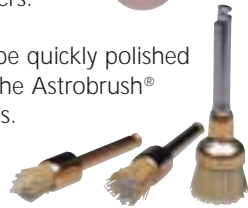

## Go for Esthetics. Go for IPS Empress Esthetic.

The adhesively luted IPS Empress Esthetic restorations can be finished with fine diamonds in the area of the adhesive cement margins and polished to a high gloss with Astropol® silicone rubber polishers.



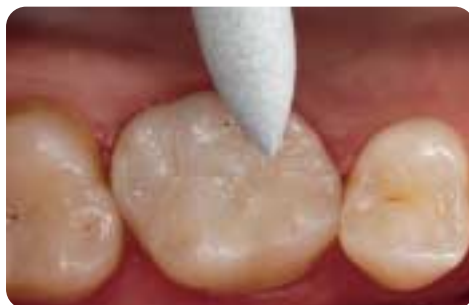The restorations can be quickly polished to a high gloss with the Astrobrush® silicon carbide brushes.



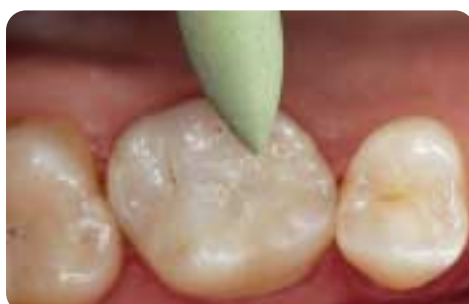### Step by Step

## Clinical case: Adhesively luted IPS Empress Esthetic inlay, polished

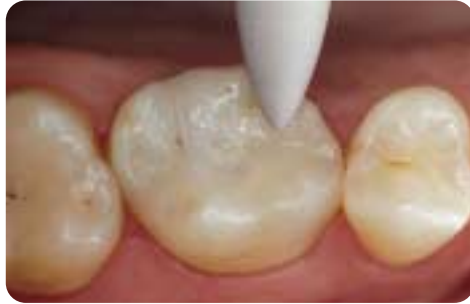Clinical case by Dr. Dr. Andreas Rathke



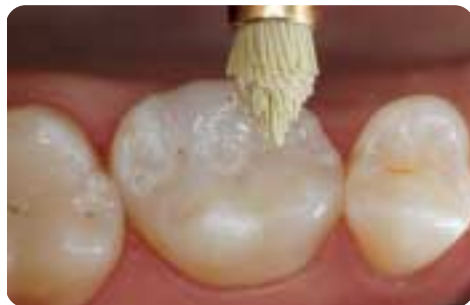Finishing of the cement margins of the adhesively luted IPS Empress Esthetic inlays with coordinated Astropol rubber polishers. First with the grey Astropol F.



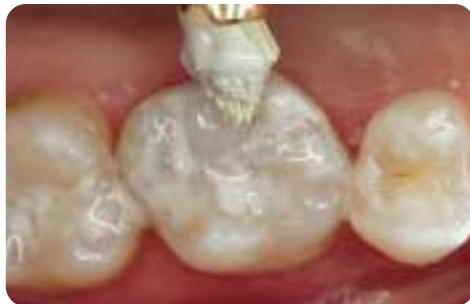Polishing with the green Astropol P.



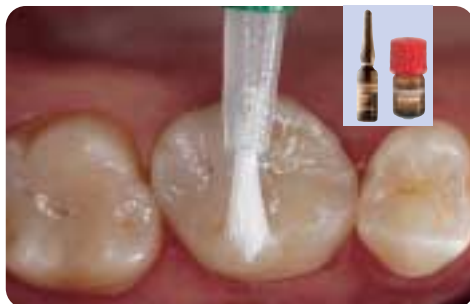High-gloss polish with the pink Astropol HP.



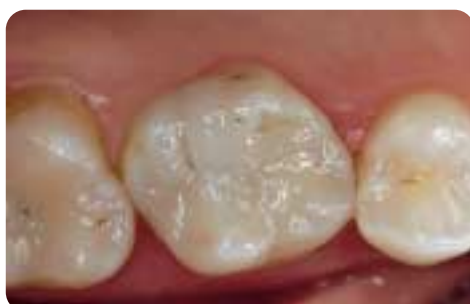For the high-gloss polish of the leucite ceramic, coated dry Astrobrush brushes are used.



A ceramic polishing paste can be applied for high-gloss polishing.

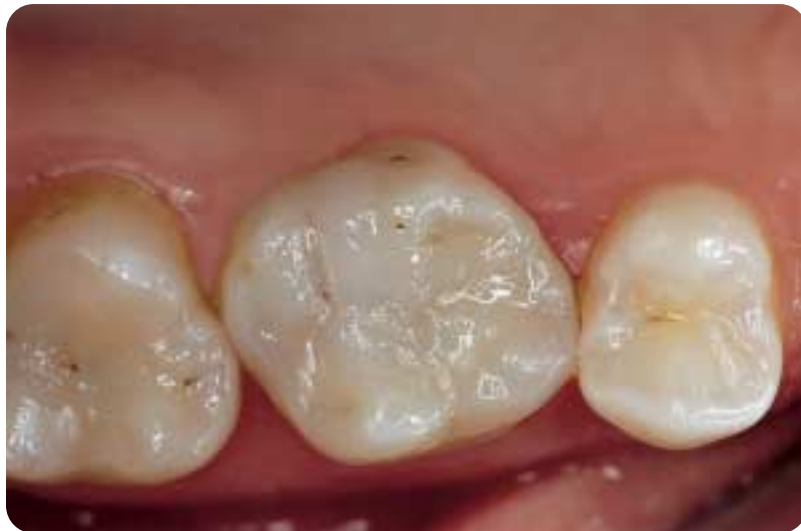
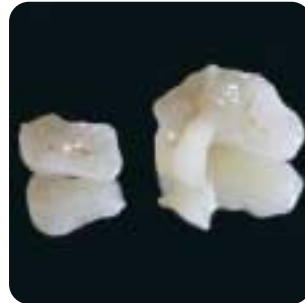
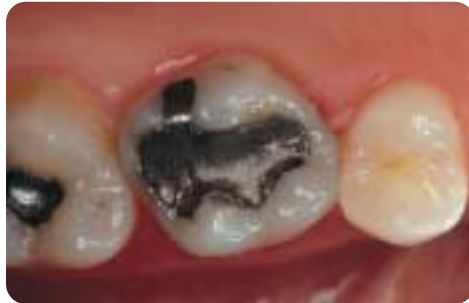After all excess material has been removed, the tooth is fluoridated with Fluor Protector.



Teeth 16 and 17 with the completed IPS Empress Esthetic inlays.

Before and after restoration with IPS Empress Esthetic





## The success rate achieved with IPS Empress is convincing

### 10-year clinical performance

IPS Empress restorations received high patient and dentist acceptance for resistance to fracture and wear and for excellent aesthetics. The Dental Advisor continues to highly recommend IPS Empress after 10 years of evaluation.

The Dental Advisor (2004); 21(3):6



### Clinical evaluation of leucite-reinforced glass-ceramic crowns over 11 years

Survival rate after 11 years: 95.2 %

M. Fradeani, M. Redemagni, Quintessenz (2003); 54:379-386

### Leucite-reinforced glass ceramic inlays and onlays after eight years in vivo

Survival rate after 8 years: 92 %

N. Kramer, A. Petschelt, R. Frankenberger, J Dent Res Spec Iss (2002); 81:Abstr. #1696:A-224

### Four-year survival rate study of IPS Empress restorations

Postoperative sensitivity with Syntac/ Variolink II and Syntac/Dual Cement accounts for less than 1 %

L. Pröbster, HJ. Ulmer, E. Engel, Ann. Conf. DGZPW (1996); Abstr. #70:59

### Six-year follow-up with IPS Empress veneers

Survival rate after 6 years: 98.8 %

M. Fradeani, Int J Periodont Rest Dent (1998); 18:217-225





